

# Excimer Laser Photorefractive Keratectomy for Keratoconus

Arun C. Gulani, MD; Lee T. Nordan, MD; Noel Alpins, FRANZCO, FRCOphth, FACS; and George Stamatelatos, BScOptom

**P**atients with keratoconus are typically frustrated with their visual limitations that negatively impact their lifestyle. These patients often have exhausted their options with glasses and contact lenses, leading them to investigate surgical options. As described within this textbook, various surgical options exist but all have drawbacks. Corneal transplant is an invasive surgery with long-term lifestyle restriction and limited ability to achieve uncorrected 20/20 vision. Intacs (Addition Technologies, Sunnyvale, CA) is a reversible, less invasive surgery that may delay or avoid transplant in many cases, but visual outcome is unpredictable. The majority of cases require contact lenses or spectacles after surgery for best correction.

In addition, these patients are typically otherwise healthy young adults at the prime of their professional and personal lives, and often have expectations similar to those searching for elective vision correction. We must therefore balance our desire to provide an enhanced lifestyle while maintaining a high level of safety for these patients.

Patients may present for surgical treatment of clinical manifestations of keratoconus including irregular astigmatism, scarring, nodules, and severe axial curvature resulting in problematic contact lens fitting. Excimer laser treatments may be applied in an effort to correct these clinical manifestations. Use of excimer treatments to remediate anterior corneal pathology is not new. Its application has been used for various conditions such as corneal scarring,<sup>1,2</sup> stromal dystrophies, keratoconus nodules,<sup>3</sup> and climatic droplet keratopathy such that transplation is avoided or delayed. Excimer treatment to reduce steepness of the cone has also been reported with an increase in visual function and no apparent progression in the disease.<sup>4-6</sup>

While treating conditions that reduce the best-corrected vision acuity (BCVA) in patients with keratoconus may be deemed “acceptable,” elective treatment of keratoconus patients to improve unaided vision is less accepted by the ophthalmic community. Reports of aberrations resulting from keratoconus corrected using topographically guided and wavefront-guided treatments are scarce but do exist. Tamayo and Serrano used the VISX C-CAP method (AMO, Abbott Park, IL), a topographically customized program, to address the topographical irregularity in keratoconus.<sup>7</sup> Koller et al used topography-guided surface ablation to significantly reduce manifest refractive error, corneal irregularity, and ghosting.<sup>8</sup> Lin et al used the Allegretto topography-guided PRK treatment (Alcon, Fort Worth, TX) in 16 keratoconic eyes. They reported improvement of astigmatism up to 5.00 D, and best spectacle-corrected visual acuity (BSCVA) unchanged or improved in 14 eyes, with 2 (12%) eyes losing 1 line of BSCVA at 6 months. Even with these results, it was not recommended unless keratoplasty was otherwise indicated in keratoconus patients.<sup>9</sup> Cennamo et al used topography-guided PRK treatments with the Zeiss Mel 70 excimer laser (Maple Grove, MN) in mild to moderate keratoconus patients (Krumeich classification, grade 2), reducing the severity of several indices used to describe the degree of keratoconus up to 2 years after treatment compared to the untreated group with keratoconus.<sup>10</sup> Use of wavefront-guided reports may be limited by the inability of aberrometers to measure irregular corneas. Bahar et al used wavefront-supported photorefractive keratectomy (PRK) in keratoconus suspects. The authors reported the treatments in this population appear to be effective, but 3 eyes suffered loss of best-corrected vision due to hazing.<sup>11</sup>

TABLE 14-1

**GULANI-NORDAN CRITERIA FOR LASER PRK IN KERATOCONUS**

- Patient is symptomatic with poor visual acuity, double vision, or glare and cannot tolerate contact lenses. Options of glasses or contact lenses are limited and/or unsuccessful.
- Clinical examination and signs suggesting corneal shape irregularity characteristic of keratoconus.
- Best-corrected visual acuity of 20/30 or better (even if with hard contact lens trial). Best corrected vision below 20/40 would indicate Intacs.
- Refraction is stable with review of prior documented exams.
- Astigmatism higher than myopia/hyperopia is preferred.
- Corneal thickness is more than 400  $\mu\text{m}$  at the thinnest point. Calculation of treatment plan determines the thinnest point should not be less than 350  $\mu\text{m}$  post-operatively.
- Corneal scar, if present, is less than the anterior one-third in depth.<sup>18</sup>
- Patient's understanding: (1) using an excimer laser in patients with keratoconus is an off-label procedure; and (2) that if due to laser treatment or natural progression their ectasia worsens, they would be candidates for other corrective procedures, such as Intacs, lamellar keratoplasty, or penetrating keratoplasty.

Correction of refractive error in patients with keratoconus may be complicated due to the nature of the disease causing instability of refractive error. However, active adults are inclined to request surgical improvement of their vision. PRK in keratoconus suspects/forme fruste keratoconus has been reported with success.<sup>12-15</sup> Successful excimer procedures have also been performed after penetrating keratoplasty, deep lamellar keratoplasty,<sup>16,17</sup> and epikeratophakia.<sup>18</sup> However, complications of excimer treatment have also been reported, including paradoxical responses<sup>19</sup> and keratolysis.<sup>20</sup> Some recommend avoiding keratorefractive procedures and correcting vision using phakic lenses to correct high amounts of myopia commonly found in keratoconus.<sup>21</sup>

While such studies suggest performing PRK for visual rehabilitation in a patient with keratoconus may be successful, performing an elective procedure on a patient whose vision may fluctuate in the future is risky. Clinical decision making and patient education become important when a mildly keratoconic patient presents for elective vision correction and achieves 20/20 vision when corrected. In such cases, performing Intacs implantation may result in a reduction of best-corrected vision and may not be the best option. Using an excimer laser surface treatment, astigmatism is addressed and uncorrected vision is improved.

The discussion may be similar to "PRK is an option because you do meet the criteria for laser surgery. We cannot guarantee how long the vision will last because your vision may drop from 20/20 to 20/40 or worse either by natural progression or perhaps by undergoing the laser

surgery. In that case, other options such as Intacs are available." Such a discussion underscores the honest desire to help keratoconic patients lead a productive life of visual freedom knowing what may be needed in the future. This may become more accepted when combined with collagen cross-linking (CXL).<sup>22</sup>

If we approach every keratoconus patient as having irregular astigmatism, we can plan for increased surgical and visual outcomes.<sup>23-26</sup>

## CRITERIA FOR ELECTIVE VISION CORRECTION

Using set criteria is useful when considering excimer treatment in a patient with early keratoconus. It guides patient education, surgical planning, and prognosis and ensures the surgeon and the patient understand the goals of the planned procedure. We have devised a set of criteria for excimer laser PRK surgery for keratoconus: the Gulani-Nordan criteria (Table 14-1). If these criteria are met, we feel it is safe to proceed with PRK. To validate this system, we applied it to a small population of patients. The authors investigated PRK in keratoconic patients including 14 eyes of 10 patients (9 men and 5 women) ranging in age from 20-66 years with follow-up ranging from 6 months to 3 years. All cases were confirmed keratoconus with present day criteria inclusive of topography.

Each patient underwent excimer surface treatment (PRK or advanced surface ablation) using standard protocol. The technique used is previously described.<sup>27</sup> Thirteen

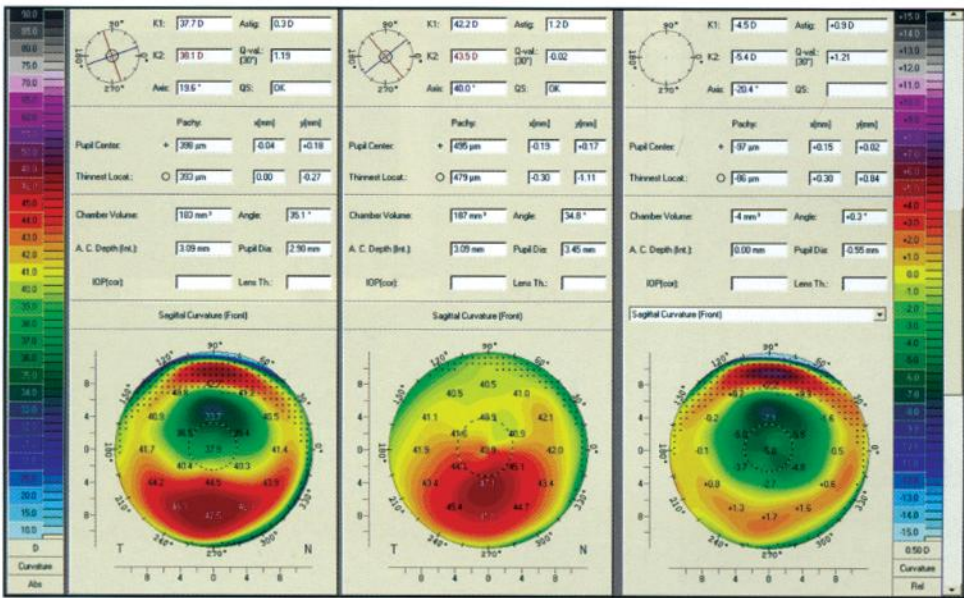


Figure 14-1. PRK for keratoconus. Pre-operative (middle) and post-operative (left) topographies with differential map (right). Post-operative vision was 20/15 unaided.

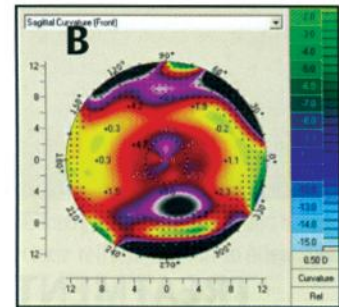



Figure 14-2. (A) PRK for pellucid marginal degeneration. The pre-operative and post-operative information is presented. Post-operative vision was 20/15 unaided. (B) Differential map of same patient.

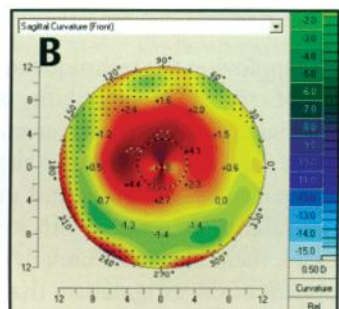


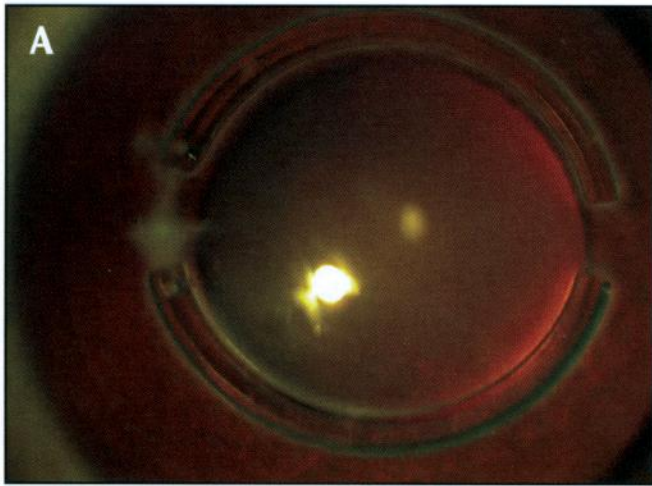
Figure 14-3. (A) PRK for keratoconus. The pre-operative and post-operative information is presented. Post-operative vision was 20/15 unaided. (B) Differential map of same patient.

of 14 eyes achieved uncorrected vision of 20/20. The last patient’s vision was limited to 20/40 due to amblyopia. Six of the 14 eyes achieved uncorrected vision of 20/15 (Figures 14-1 through 14-3).

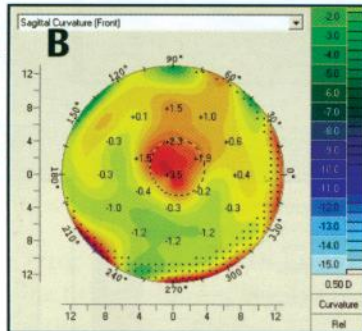
Subjective success of treatment was based on uncorrected visual acuity and patient’s subjective response. Patients were asked to compare the post-operative vision to pre-operative vision using a grading scale of 1 to 10 (10 being the best). All the patients treated reported a subjective evaluation grade of 10. All patients stated that they

had no complaints at night and all noted that their vision at night was improved compared to best corrected vision pre-operatively.

In all cases, excimer laser ablation was calculated to ensure reasonable post-operative corneal thickness to allow Intacs implantation at a later date should the condition progress (Figure 14-4). One can also treat patients previously operated with Intacs to correct residual astigmatism with laser vision surgery in the PRK mode, though one needs to be mindful of increased haze risk in these eyes.



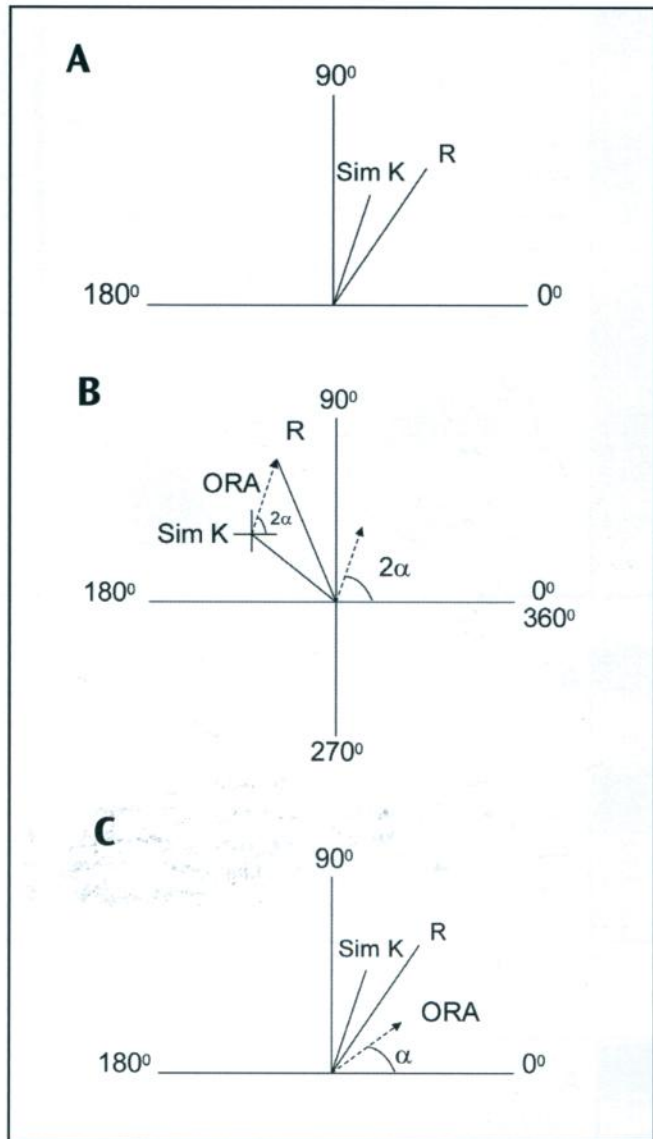
**Figure 14-4.** (A) Double Intacs segment implantation for keratoconus, followed by PRK for improvement in unaided vision. (B) Differential topography map of laser post-Intacs. The patient in 14-4A enjoyed vision unaided of 20/25.



## TREATMENT OF MYOPIC ASTIGMATISM IN KERATOCONUS USING PARK

Employing the technique of vector planning and a number of criteria for the stability of this ectatic condition, photoastigmatic refractive keratectomy (PARK) has been shown to be safe and effective in the treatment of myopic astigmatism in forme fruste and mild keratoconus. Despite the irregularity associated with keratoconic corneas, in milder cases, there also is an underlying quantifiable regular component of the astigmatism that is treatable in a symmetrical manner. This regular component can commonly be gauged by the simulated keratometry value from topography, as well as the measured value by manual keratometry.

While zero overall astigmatism is an ideal outcome of refractive laser surgery, this result is effectively unattainable in eyes with keratoconus due to a poorer correlation between corneal (topography or keratometry) and refractive (wavefront or manifest) astigmatism values compared to the values for a normal astigmatic population.<sup>28-31</sup> This prevailing difference between these 2 astigmatic parameters is quantified by the ocular residual astigmatism (ORA)<sup>28-32</sup> and where it exists in a significant amount, the eye's optical system cannot be completely corrected for astigmatism by refractive laser treatment.



**Figure 14-5.** (A) Calculating ORA: Polar diagram of refractive wavefront cylinder at the positive axis and simulated keratometry from the topography. (B) The DAVID showing a “doubling” of the angles without a change in the astigmatic magnitudes. (C) Polar diagram displaying the ORA as it would appear on the eye. (ORA=ocular residual astigmatism; R=refractive wavefront astigmatism [corneal plane]; Sim K=simulated keratometry from topography).

The ORA is determined by calculating the vectorial difference between the wavefront or manifest refraction measurements for refractive cylinder and topography or keratometry measurements for corneal astigmatism.<sup>29,30,32</sup> Doubling the axes of the astigmatism while leaving the magnitudes unchanged allows for the conversion of polar coordinates to rectangular coordinates. The ORA being a vector quantity connecting the 2 astigmatism on this mathematical construct is then transferred to the origin ( $x=0, y=0$ ) and halved to simulate how it would exist within the eye (Figure 14-5). This vectorial difference, measured in diopters and degrees and calculated using basic

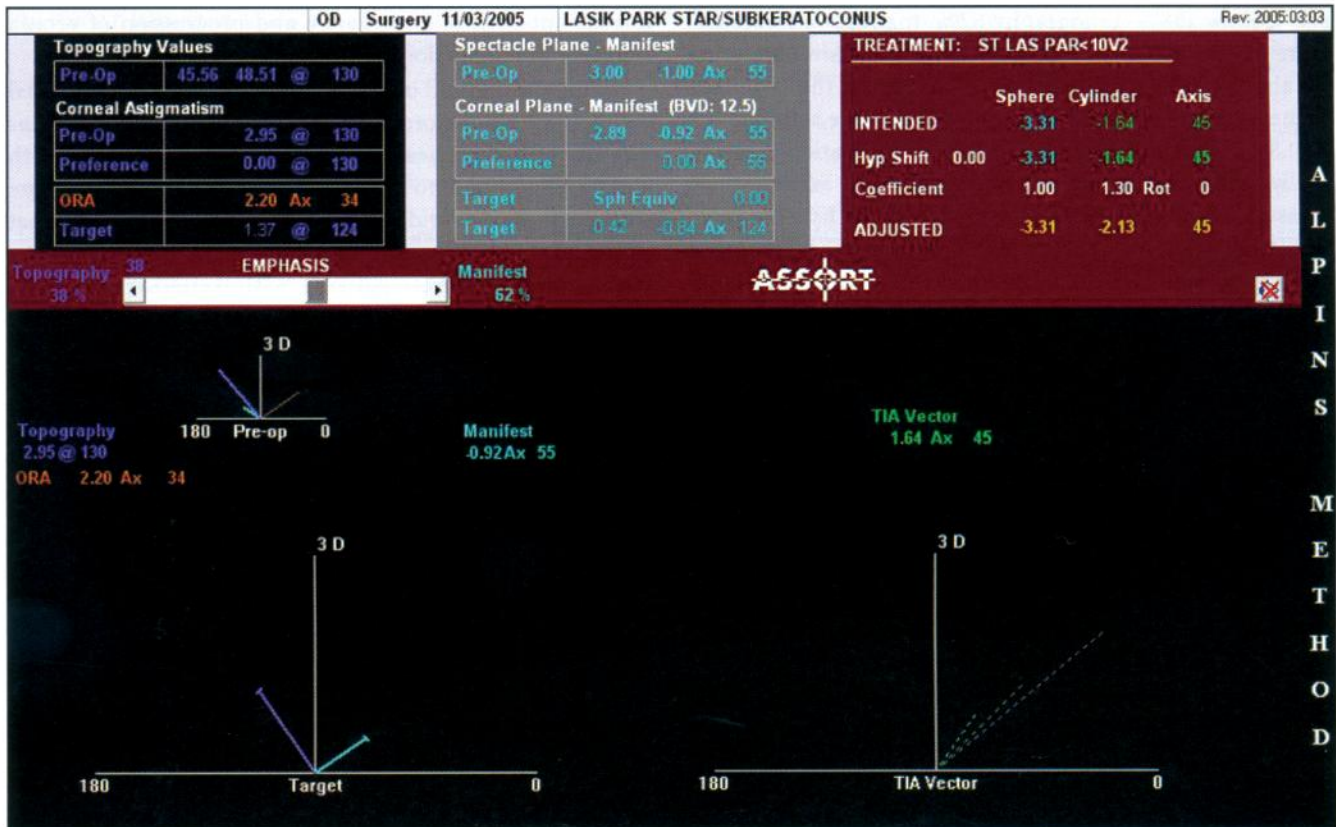


Figure 14-6. ASSORT Treatment Planning screen shows how the ORA of 2.20 D Ax 34 is apportioned 38% to eliminating the topography astigmatism and 62% to the refractive cylinder. Furthermore, this ORA is neutralized by an equivalent 1.37 D at the cornea and 0.84 D at the spectacle refraction but at an orientation of 124 degrees.

trigonometric principles, has a proportional relationship with astigmatism. As the astigmatic difference between refractive and corneal astigmatism increases, the magnitude of the ORA also increases. Therefore, the amount of remaining post-operative astigmatism in the ocular system will also inevitably be greater. This uncorrectable astigmatism is left on the cornea using conventional refractive techniques to neutralize the internal ocular astigmatism quantified by the ORA and leads to increased aberrations and a reduction in the quality of vision.

Using vector planning aids in avoiding poor outcomes by distributing the neutralization of the ORA between the cornea and the refraction. The technique of vector planning reduces a greater amount of corneal astigmatism than treatment using refractive parameters alone. As a result, fewer second- and third-order aberrations remain.<sup>28-32</sup>

The Alpains Method of vector planning was used for the treatment of astigmatism in a retrospective study of 45 eyes with forme fruste or mild keratoconus.<sup>32</sup> Due to the irregular shape of these corneas, surface ablation with PARK was performed in each case. The minimum requirements to be eligible for surgical treatment included a best corrected visual acuity (BCVA) of better than or equal to 20/40 and a non-progressive cone displaying refractive and corneal

stability over a minimum 2-year period. The minimum age criterion was 25 years. Those with average K readings  $\geq 50.00$  D power, visible ectasia or scarring under slit-lamp examination, and residual stromal bed less than 300  $\mu\text{m}$  (allowing for epithelial thickness of 60  $\mu\text{m}$ ) were excluded.

The mean astigmatism values pre-operatively were  $-1.39 \text{ DC} \pm 1.08$  by manifest refraction and  $1.70 \text{ D} \pm 1.42$  by topography. Post-operatively, 45 eyes were reviewed at 1 year, 32 eyes at 5 years, and 9 eyes at 10 years for stability in the corneal astigmatism and refractive cylinder measurements. Average corneal keratometry values were also followed to identify signs of progressive ectasia.

In this study group, all the treatments were optimized; that is, the emphasis on the ORA neutralization was determined by targeting reduced corneal astigmatism optimized to a with-the-rule orientation of the remaining astigmatism in a linear relationship. As a result a beneficial effect of less astigmatism remaining overall (corneal *plus* refractive measurements) was achieved after the surgery.

By incorporating the corneal parameters as well as the refractive astigmatism parameters into the overall treatment (Figure 14-6), less corneal astigmatism is being targeted. In this example, shifting the emphasis for astigmatism reduction “to the left” by 38 emphasis percent-

A  
L  
P  
I  
N  
S  
M  
E  
T  
H  
O  
D

age points (38% topography/62% manifest refraction) increases the proportion of corneal astigmatism correction by aligning the treatment more closely to the principal corneal meridian.<sup>32,34</sup> The targeted refractive astigmatism of 0.84 D may not be fully evident to the patient perceptually where a spherical equivalent of zero exists. When measurements were in fact taken at 6 months, simulated keratometry showed 1.25 D @ 126 degrees while manifest refraction measured  $-0.25$  DC Ax 45 (less than anticipated) confirming the value of this optimized approach.

It is important to highlight that no matter what the percentage chosen on the “emphasis” bar, the minimum amount of total astigmatism (corneal *plus* refractive), which is equal to the ORA, is being targeted at every point on the percentage scale. If the combined magnitude of the remaining astigmatism (corneal *plus* refractive) is greater than the initial ORA, the surgery then fails to achieve the maximum astigmatism treatment. Even though all the astigmatism is not correctable, results with this technique were still significantly better than they would have been using conventional refractive astigmatism values alone. Treatment using refractive parameters alone would theoretically result in 2.20 D (that is, all the ORA) remaining on the cornea. Incorporating the corneal values into the treatment profile reduced the total astigmatism in the system post-operatively to 1.50 D (1.25 D corneal + 0.25 D manifest refraction). This particular patient also had an improvement in BCVA from 20/20 to 20/15 as well as the improvement in unaided visual acuity (UCVA) from 20/200 to 20/20.

This favorable outcome of compounding the reduction of overall total astigmatism was common in many cases within the group of 45 eyes and also evident in the aggregate results where topography values have been incorporated into the treatment plan.

Within the study, post-operative results at 12 months found a reduction of corneal astigmatism by an additional 0.68 D compared to theoretical results attained by treating refractive values alone. This was achievable without compromising the refractive outcome. UCVA at 1 year post-operatively showed 100% of eyes  $\geq$  20/40, 89% of eyes  $\geq$  20/30, 56% of eyes  $\geq$  20/20. BCVA pre-operatively and at 1 year was 89%  $\geq$  20/20 and 100%  $\geq$  20/30. Gains and losses in BCVA revealed an excess of gain over loss: 1 eye had 2 lines loss, 6 eyes 1 line loss, 22 eyes unchanged, 13 eyes had 1 line gain, and 3 eyes had 2 lines gain.

This treatment paradigm of combining either corneal (topography or keratometry) parameters with refractive measurements has been shown to be safe and effective in this study of 45 eyes with forme fruste and mild keratoconus. These eyes post-operatively had a stable refraction and corneal topography over an extended period of time up to 10 years post-operatively. This is true both in terms of non-progression of disease and favorable spherical and astigmatic refractive outcomes. No problems or adverse signs such as

increase in corneal irregularity and progression of ectasia resulting in a reduction of UCVA or BCVA were detected.

Using the method of vector planning, there is a potential for reduced higher-order aberrations (coma and trefoil) as a result of less corneal astigmatism post-operatively with greater likelihood to achieve an improved BCVA more frequently and avoid adverse symptomatic effects that would likely occur with treatments based solely on refractive values. However, patients with keratoconus evaluated for photorefractive keratectomy should be carefully selected<sup>35,36</sup> and followed over time to determine stability of manifest refraction and corneal topography prior to surgical intervention. It is extremely unlikely that the treatment of irregular corneas as a result of keratoconus can achieve universally excellent outcomes without the inclusion of corneal parameters. The technique of vector planning is not restricted to the treatment of astigmatism in keratoconus patients but can be more routinely applied to the treatment paradigm of normal astigmatic corneas when performing laser vision correction.

## CONCLUSION

Excimer treatment appears to be successful for treatment of sequela of keratoconus, including scarring, steep cones, and nodules. The treatment of myopic astigmatism is safe and effective in selected cases of forme fruste and mild keratoconus with careful patient education, ensuring patients meet criteria to ensure safety, and using vector planning, the treatment has less potential adverse impact upon visual outcome and progression.

## REFERENCES

1. Ayres BD, Rapuano CJ. Excimer laser phototherapeutic keratectomy. *Ocul Surf*. 2006;4(4):196-206.
2. Ward MA, Artunduaga G, Thompson KP, Wilson LA, Stulting RD. Phototherapeutic keratectomy for the treatment of nodular subepithelial corneal scars in patients with keratoconus who are contact lens intolerant. *CLAO J*. 1995;21(2):130-132.
3. Elsahn AF, Rapuano CJ, Antunes VA, Abdalla YF, Cohen EJ. Excimer laser phototherapeutic keratectomy for keratoconus nodules. *Cornea*. 2009;28(2):144-147.
4. Mortensen J, Carlsson K, Ohrström A. Excimer laser surgery for keratoconus. *J Cataract Refract Surg*. 1998;24(7):893-898.
5. Mortensen J, Ohrström A. Excimer laser photorefractive keratectomy for treatment of keratoconus. *J Refract Corneal Surg*. 1994;10(3):368-372.
6. Moodaley L, Buckley RJ, Woodward EG. Surgery to improve contact lens wear in keratoconus. *CLAO J*. 1991;17(2):129-131.
7. Tamayo GE, Serrano MG. Treatment of irregular astigmatism and keratoconus with the VISX C-CAP method. *Int Ophthalmol Clin*. 2003;43(3):103-110.
8. Koller T, Iseli HP, Donitzky C, Ing D, Papadopoulos N, Seiler T. Topography-guided surface ablation for forme fruste keratoconus. *Ophthalmology*. 2006;113(12):2198-2002.

9. Lin DT, Holland SR, Rocha KM, Krueger RR. Method for optimizing topography-guided ablation of highly aberrated eyes with the ALLEGRETTO WAVE Excimer Laser. *J Refract Surg.* 2008;24(4):S439-S445.
10. Cennamo G, Intravaja A, Boccuzzi D, Marotta G, Cennamo G. Treatment of keratoconus by topography-guided customized photorefractive keratectomy: two-year follow-up study. *J Refract Surg.* 2008;24(2):145-149.
11. Bahar I, Levinger S, Kremer I. Wavefront-supported photorefractive keratectomy with the Bausch & Lomb Zyoptix in patients with myopic astigmatism and suspected keratoconus. *J Refract Surg.* 2006 Jun;22(6):533-538.
12. Bilgihan K, Ozdek SC, Konuk O, Akata F, Hasanreisoglu B. Results of photorefractive keratectomy in keratoconus suspects at 4 years. *J Refract Surg.* 2000;16(4):438-443.
13. Sun R, Gimbel HV, Kaye GB. Photorefractive keratectomy in keratoconus suspects. *J Cataract Refract Surg.* 1999;25(11):1461-1466.
14. Appiotti A, Gualdi M. Treatment of keratoconus with laser in situ keratomileusis, photorefractive keratectomy, and radial keratotomy. *J Refract Surg.* 1999;15(2 Suppl):S240-S242.
15. Doyle SJ, Hynes E, Naroo S, Shah S. PRK in patients with a keratoconic topography picture. The concept of a physiological 'displaced apex syndrome'. *Br J Ophthalmol.* 1996;80(1):25-28.
16. Pedrotti E, Sbabo A, Marchini G. Customized transepithelial photorefractive keratectomy for iatrogenic ametropia after penetrating or deep lamellar keratoplasty. *J Cataract Refract Surg.* 2006;32(8):1288-1291.
17. Leccisotti A. Photorefractive keratectomy with mitomycin C after deep anterior lamellar keratoplasty for keratoconus. *Cornea.* 2008;27(4):417-420.
18. Xie L, Gao H, Shi W. Long-term outcomes of photorefractive keratectomy in eyes with previous epikeratophakia for keratoconus. *Cornea.* 2007;26(10):1200-1204.
19. Fraenkel G, Sutton G, Rogers C, Lawless M. Paradoxical response to photorefractive treatment for postkeratoplasty astigmatism. *J Cataract Refract Surg.* 1998;24(6):861-865.
20. Lahners WJ, Russell B, Grossniklaus HE, Stulting RD. Keratolysis following excimer laser phototherapeutic keratectomy in a patient with keratoconus. *J Refract Surg.* 2001;17(5):555-558.
21. Kamiya K, Shimizu K, Ando W, Asato Y, Fujisawa T. Phakic toric Implantable Collamer Lens implantation for the correction of high myopic astigmatism in eyes with keratoconus. *J Refract Surg.* 2008;24(8):840-842.
22. Kanellopoulos AJ, Binder PS. Collagen cross-linking (CCL) with sequential topography-guided PRK: a temporizing alternative for keratoconus to penetrating keratoplasty. *Cornea.* 2007;26(7):891-895.
23. Gulani AC. Corneoplastique. *Techniques in Ophthalmology.* 2007;5(1):11-20.
24. Gulani AC. A new concept for refractive surgery: corneoplastique. *Ophthalmology Management.* 2006;10(4):57-63.
25. Gulani AC. Corneoplastique: art of vision surgery (Abstract). *Journal of American Society of Laser Medicine and Surgery.* 2007;19:40.
26. Gulani AC. Corneoplastique. *Video Journal of Cataract and Refractive Surgery.* 2006;22(3).
27. Gulani AC. Excimer laser PRK : refractive surgery to the rescue. In: *Mastering Advanced Surface Ablation Techniques.* J.P. Publishers: India; 2007:246-248.
28. Alpíns NA. Treatment of irregular astigmatism. *J Cataract Refract Surg.* 1998;24:634-646.
29. Alpíns N. Astigmatism analysis by the Alpíns method. *J Cataract Refract Surg.* 2001;27:31-49.
30. Alpíns NA. New method of targeting vectors to treat astigmatism. *J Cataract Refract Surg.* 1997;23:65-75.
31. Goggin M, Alpíns N, Schmid L. Management of irregular astigmatism. *Current Opinion in Ophthalmology.* 2000;11:260-266.
32. Alpíns NA, Stamatelatos G. Customized PARK treatment of myopia and astigmatism in forme fruste and mild keratoconus using combined topographic and refractive data. *J Cataract Refract Surg.* 2007;33:591-602.
33. Alpíns NA. Wavefront Technology: A new advance that fails to answer old questions on corneal vs. refractive astigmatism correction. *J Cataract Refract Surg.* 2002;18:737-739.
34. Alpíns NA, Vector analysis of astigmatism changes by flattening, steepening, and torque. *J Cataract Refract Surg.* 1997; 23:1503-1514.
35. Binder P, Lindstrom R, Stulting R, et al. Keratoconus and corneal ectasia after LASIK. *J Cataract Refract Surg* 2005; 31: 2035-2037.
36. Colin S, Velou S. Current surgical options for keratoconus. *J Cataract Refract Surg.* 2003;29:379-386.

Financial Disclosure: Dr. Alpíns is the founder of ASSORT Pty Ltd.